

# Osgood-Schlatter disease

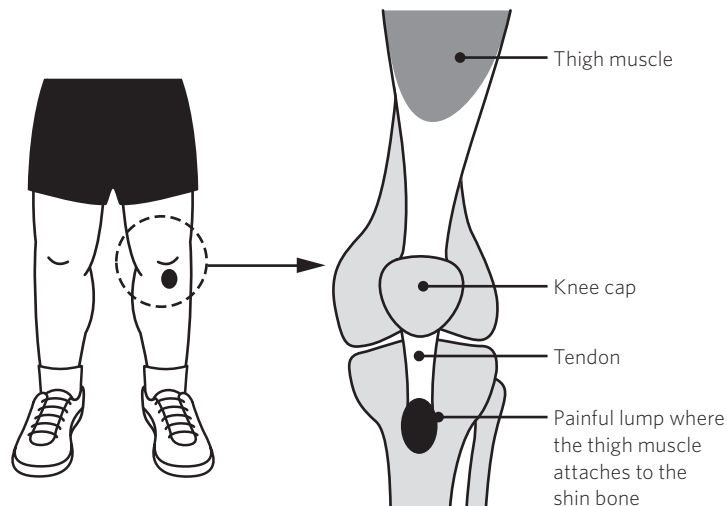
## ORTHOPAEDIC FACT SHEET

Osgood-Schlatter disease is a common cause of pain in front of the knee in late childhood and early adolescence. It is more common in boys. One or both knees may be affected. The condition often occurs in children who are highly active, particularly in sports involving running and jumping.

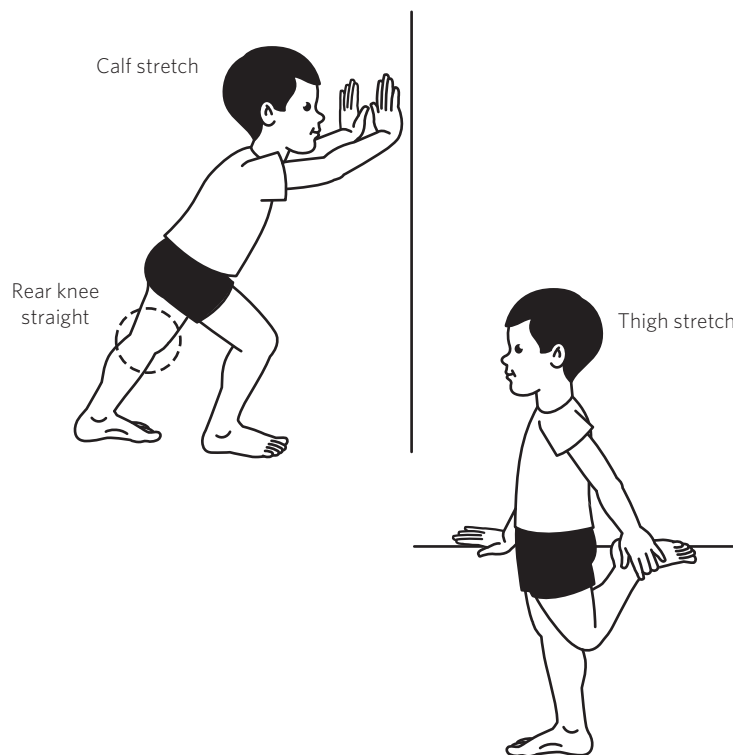
In Osgood-Schlatter disease, repeated running and jumping leads to a small injury where the thigh muscle attaches to the shin bone just below the knee cap (**Figure 1**). This causes a painful lump. Pain is usually worse during or just after activity, and tends to improve with rest.

Osgood-Schlatter disease is diagnosed by clinical examination. Special tests or X-rays are generally not necessary. Treatment is aimed at relieving discomfort. Continuing sport or physical activity is not harmful but may make the pain worse, and it is better to stop or modify the activities that cause pain. Taping or a protective sleeve worn over the area may be helpful for sports, and symptoms can be treated with ice packs. Strengthening and gentle stretching of lower limb muscles is also recommended (**Figure 2**).

Pain associated with Osgood-Schlatter's goes away when growth is finished. The lump may remain prominent, which can occasionally cause discomfort when kneeling.



**Figure 1.** Anatomy of Osgood-Schlatter disease



**Figure 2.** Stretches for Osgood-Schlatter disease